PART 12 | Genitourinary

CHAPTER

87 Gynaecology

Learning objectives

To understand:

- Pelvic anatomy
- Early pregnancy complications (ectopic pregnancy)
- Common causes of an acute abdomen and chronic abdominal pain
- Causes of abnormal uterine bleeding in the non-pregnant state
- Surgical management of endometriosis, adenomyosis, uterine fibroids, uterovaginal prolapse and ovarian tumours

ANATOMY

The reproductive structures of the dividing embryo differentiate after the seventh week of development. The gonads and internal and external genitalia constitute the sex organs. In the female, the Müllerian ducts develop into the uterus, fallopian tubes, cervix and upper third of the vagina. The urogenital sinus in turn forms the lower two-thirds of the vagina.

The female external genitalia are described as the vulva, which is bordered by the mons pubis anteriorly and the labiocrural folds posterolaterally. The opposing skin that covers the introitus is known as the labia majora. The labia minora are folds of skin that fuse anteriorly around the clitoris, which contains erectile tissue similar to the penis in the male. The posterior part of the introitus is referred to as the fourchette and this stretches considerably during childbirth to allow delivery of the baby.

The vagina is an elastic, distensible tube, approximately 6–7 cm long, passing upwards and backwards from the introitus. The cervix protrudes into the vault of the vagina, dividing it into the anterior, posterior and lateral fornices. Pelvic structures can be felt in the posterior and lateral fornices on bimanual examination, as the vaginal vault sits just below the pouch of Douglas (the area at the bottom of the pelvic cavity bordered by the uterus anteriorly and rectum posteriorly). The urethra and bladder neck sit above the anterior wall of the vagina; the perineal body and rectum behind the posterior wall (*Figure 87.1*).

The uterus consists of a body and a cervix (neck of the uterus) and is an upside-down pear-shaped structure that is flattened anteroposteriorly, giving its cavity a flat, triangular shape. The uterus is supported partly by ligaments attached to the cervix (transverse cervical, pubocervical and uterosacral) that consist of condensed connective tissue. The cervix is a canal, approximately 2–3 cm long in the non-pregnant woman, connecting the external os, which can be seen on speculum examination, to the internal os, where the cervix enters the uterine cavity. The uterine cavity to cervical length ratio varies through hormonal influences and developmental phases, with the uterine body increasing in size as puberty progresses.

The cervical canal is located within the centre of the bony cavity of the pelvis, with the uterus pivoted around this point. It is more commonly angled forwards (anteverted) relative to the vagina. It is usually freely mobile, with filling of the bladder

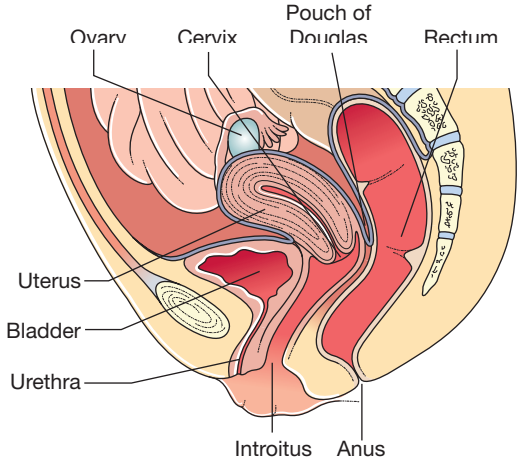

Figure 87.1 Female anatomy.

Johannes Peter Müller, 1801–1858, Professor of Anatomy and Physiology, Berlin, Germany, described the paramesonephric duct in 1825.
James Douglas, 1675–1742, anatomist, midwife and physician to Queen Caroline, London, UK, helped expose the fraudulent claims of Mary Toft, who, in 1726, famously tricked a number of doctors into believing that she had given birth to rabbits.
Gabriele Falloppio (Fallopius), 1523–1563, Professor of Anatomy, Surgery and Botany, Padua, Italy. He carried out what may have been the first clinical trial in over 1000 men of the use of condoms to prevent transmission of syphilis.

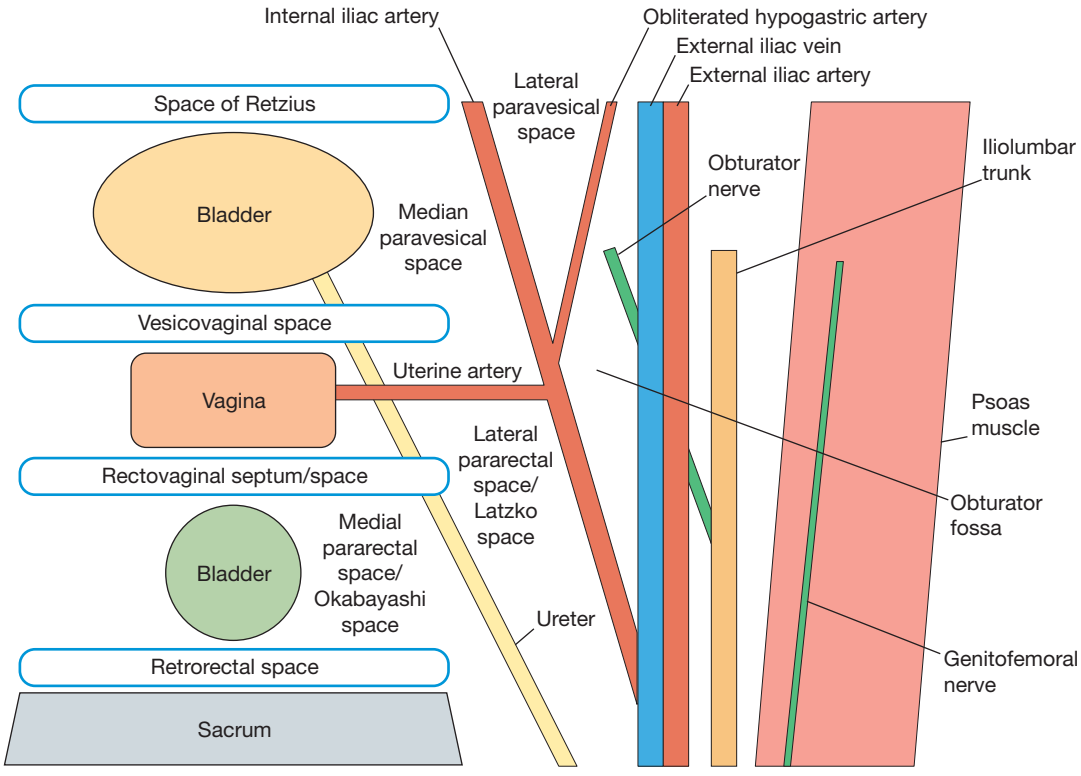

Figure 87.2 Surgical anatomy of the pelvis, including the key surgical spaces, vessels and nerves in relation to the pelvic organs (illustrative representation of anatomical spaces by PR Supramaniam).

or changes in position rotating it backwards. In others, it can be retroverted, a variation of normal, or secondary to weak ligaments or because it becomes adherent as the result of a disease process such as endometriosis. The uterus may also be angled forwards (anteflexed) relative to the cervix or backwards (retroflexed), which can be determined through bimanual examination.

The uterine walls are 1–2 cm thick and composed of smooth muscular tissue (myometrium). The uterine cavity is lined with endometrium, a tissue that undergoes cyclical changes in response to ovarian hormones. The endometrium has both a basal and functional layer. The basal layer lies adjacent to the myometrium and from it develops the functional layer. The basal layer is not shed during menstruation, unlike the functional layer. The functional layer is influenced by oestrogen and progesterone, which thicken it, preparing the lining for implantation. This layer is completely shed during menstruation should conception not occur.

In the lean patient, the uterine size can be estimated on palpation. This is usually a subjective assessment outside of imaging modalities. The most common cause of an enlarged uterus, apart from pregnancy, is fibroids (benign tumours of the myometrium) growing inside or outside of the uterus. In the presence of fibroids or other conditions causing enlargement of the uterus, the uterine size is often described in terms of the number of weeks' gestation it approximates to, were the woman pregnant.

At the uterine fundus, on either side, are the cornua, which connect the uterus to the fallopian tubes. These are thin, muscular tubes, approximately 10 cm long. They are divided into four parts: intramural, isthmus, ampulla and the fimbriated opening, which picks up the oocyte following its release at the time of ovulation. The tubes are very narrow in the isthmic and intramural parts but widen at the ampullary region. Each tube is contained within the upper part of the broad ligament, a fold of peritoneum on either side of the uterus, which also contains blood vessels as well as the round and ovarian ligaments. The fimbriated opening and part of the ampulla, however, are free and closely associated with the ovary on either side. The ovaries are flattened, ovoid structures, approximately 3–4 cm in dimension, suspended from the back of the broad ligament on either side of the pelvic side wall by the ovarian ligament, which originates from the uterine body. The ovarian blood vessels are contained within the infundibulopelvic ligaments, which are continuations of the broad ligament to the pelvic brim on either side.

A sound understanding of pelvic anatomy is key to surgical excellence and safety (***Figure 87.2***).

The sacral promontory is considered a crucial landmark and the summit of the pelvis. While pelvic pathology may reach into the abdominal cavity, the origin is always below the sacral promontory. The sacrum is a bony prominence that is used as a point of reference in surgery and in surgical anatomy. The sacral promontory is the level at which the common iliac vessels bifurcate into the external and internal iliac vessels, and the level at which the ureter transverses from the lateral to medial side. Another key structure at this level is the superior hypogastric nerve plexus (autonomic nerve plexus), which is

formed from the convergence of the right and left hypogastric nerves.

The aorta bifurcates at the level of the L4 vertebral body, where it forms the right and left common iliac vessels. The common iliac vessel then further bifurcates as described above at the level of the sacral promontory. The external iliac artery mainly supplies the lower limbs and has one anterior branch known as the inferior epigastric artery. Note should be made of the position of this artery when determining placement of lateral ports during laparoscopy, to avoid vascular injury. The internal iliac artery divides further into the anterior and posterior divisions. The anterior division is the main blood supply to the vital organs of the pelvis. The posterior division mainly supplies the gluteal region. The anterior division travels parallel to the ureter and gives off its first branch, the uterine artery, followed by the superior vesical artery, and continues as the obliterated umbilical artery. There is often a 5- to 6-cm distance from the origin of the anterior division prior to the first branch. This is often the level at which surgeons perform internal iliac artery ligation to manage cases of massive haemorrhage during obstetric surgery and prophylactically in pelvic exenteration surgery.

The pelvic structures are supplied by the autonomic nervous system. The inferior hypogastric nerve (T10–L2) provides sympathetic fibres and the pelvic splanchnic nerve provides parasympathetic fibres. These fibres merge to supply both the ureter and urinary bladder and can often be injured in complex pelvic surgery, leading to complications of residual bladder dysfunction and sexual dysfunction.

Pelvic spaces have recently featured in surgical anatomy as a key learning point to aid surgeons in performing safe surgery. The retroperitoneal spaces are divided into those that are present bilaterally (pararectal and paravesical spaces) and those that are present in the midline (space of Retzius, rectovaginal space and the retrorectal space). The pararectal space is bound medially by the rectum and laterally by the internal iliac artery. The posterior leaf of the broad ligament forms the roof and the levator ani muscle forms the floor. Cranially, the space is bordered by the uterine artery. The pararectal space is further divided into medial and lateral spaces by the ureter, with the medial pararectal space also known as the Okabayashi space and the lateral pararectal space called the Latzko space.

The paravesical space is a retroperitoneal space that is lateral to the urinary bladder. Medially it is bound by the urinary bladder, laterally by the pelvic walls and inferiorly by the uterine artery. The paravesical space is further divided into medial and lateral spaces by the obliterated hypogastric artery. The floor of the medial paravesical space is formed by the levator ani muscle. The obturator and pelvic lymph nodes are contained in the lateral paravesical space, important during a radical hysterectomy, and the limit of dissection is bounded by the posterior limit of the obturator nerve.

The space of Retzius is the midline retroperitoneal space between the bladder and the anterior abdominal wall. It is connected to the paravesical space and is enclosed laterally by the obliterated hypogastric artery. This space is often used in urogynaecological procedures as the bladder neck is exposed, aiding surgery performed for incontinence. It is also used in deep endometriosis surgery during management of bladder nodules to aid in tension-free closure of the cystotomy.

The rectovaginal space refers to the posterior retroperitoneal space that is formed by the uterus anteriorly and the rectum posteriorly. The lateral borders of this space are provided by the uterosacral ligament. This space is often explored to aid in radical hysterectomy and deep endometriosis surgery.

The retrorectal space is a retroperitoneal space that is bound by the rectum anteriorly. It is often explored in complex pelvic surgery and deep endometriosis surgery associated with excision of the rectum. The presacral vein that lies posterior to Waldeyer's fascia is often an area of concern because, if not carefully dissected, it can lead to severe uncontrollable haemorrhage.

EARLY PREGNANCY COMPLICATIONS

Ectopic pregnancy

An ectopic pregnancy refers to a pregnancy that grows outside of the uterine cavity, most commonly within the fallopian tube. To facilitate management of an ectopic pregnancy it is important to be able to describe the location of the pregnancy as accurately as possible. The newly agreed terminology broadly divides ectopic pregnancies into uterine (defined by evidence of trophoblast invasion beyond the endometrial–myometrial junction, but not outside the uterine visceral/broad ligament peritoneum) and extrauterine ectopic pregnancies (***Table 87.1***). They are further described as being complete (solely confined to the myometrium) or partial (involving both the myometrium and the uterine cavity).

Additional variations include rudimentary horn pregnancies. These are rare, with a reported incidence of 1 in 75 000–150 000 pregnancies. They are able to develop into the second trimester if not diagnosed early through the identification of a single interstitial portion of the fallopian tube attached to the main unicornuate uterine body, with products of conception completely surrounded by myometrium, presenting with severe pain and uterine rupture.

A residual ectopic pregnancy refers to an ectopic pregnancy that remains visible on ultrasound scan 3 months after a negative urinary pregnancy test and serum beta-human chorionic gonadotropin (βHCG) level of <20 IU/L.

As the ectopic pregnancy grows, the placental tissue can infiltrate the blood vessels surrounding the fallopian tube, leading to bleeding within the tube and into the peritoneal cavity. Further growth of the ectopic pregnancy can rupture the fallopian tube, causing significant intraperitoneal blood

Anders Retzius, 1796–1860, Swedish anatomist.
Hidekazu Okabayashi, 1884–1953, Japanese gynaecologist, demonstrated the first nerve-sparing radical hysterectomy in Kyoto Imperial University Hospital, Kyoto, Japan, 1921.
Wilhelm Latzko, 1863–1945, Austrian gynaecologist, described a technique for vaginal closure of vesicovaginal fistula following a hysterectomy, 1914.
Heinrich Wilhelm Gottfried Waldeyer-Hartz, 1836–1921, Professor of Pathological Anatomy, Berlin, Germany.

TABLE 87.1 Examples of uterine and extrauterine ectopic pregnancies.

Uterine ectopic pregnancies	Extrauterine ectopic pregnancies
• Cervical (the gestational sac is present below the level of the internal os with absence of the 'sliding sign' and evidence of blood flow around the gestational sac using colour Doppler) • Caesarean scar (the gestational sac is located low in the uterus, close to the internal os with trophoblast invading into the anterior myometrium) (*Figure 87.3*) • Intramural (located above the level of the internal os)	• Tubal (*Figure 87.4*) (further divided into interstitial [*Figure 87.5*], isthmic and ampullary) • Ovarian (colour Doppler can help identify an area of increased vascularity within the ovary that is representative of peritrophoblastic blood flow separate from that of the corpus luteum) (*Figure 87.6*) • Abdominal (commonly the broad ligament, pouch of Douglas, uterovesical pouch and surfaces of the tubes and uterus)

loss. This constitutes a gynaecological emergency. An ectopic pregnancy occurs in 11 per 1000 pregnancies, and there is a maternal mortality rate of 0.2 per 1000 estimated ectopic pregnancies. The major risk factors for an ectopic pregnancy are shown in ***Summary box 87.1***.

Summary box 87.1

Risk factors for an ectopic pregnancy

- Previous pelvic inflammatory disease (PID)
- Smoking
- History of infertility
- Use of an intrauterine contraceptive device (IUCD)
- Previous ectopic pregnancy
- Previous abdominal/pelvic surgery, e.g. myomectomy, hysteroscopic resection
- Previous tubal surgery, e.g. sterilisation, salpingostomy, tuboplasty
- Endometriosis

An ectopic pregnancy may be suspected on clinical grounds, but making the diagnosis can be difficult (***Table 87.2***).

TABLE 87.2 Symptoms and signs of an ectopic pregnancy.

Symptoms	Signs
• Abdominal or pelvic pain • Amenorrhoea or missed period • Vaginal bleeding • Breast tenderness • Gastrointestinal symptoms • Dizziness, fainting, syncope • Shoulder tip pain • Rectal pressure or pain on defecation • Asymptomatic	• Pelvic, abdominal and/or adnexal tenderness or fullness • Signs of peritonism • Pallor • Abdominal distension • Cervical motion tenderness (pain on moving the cervix) • Enlarged uterus • Tachycardia, hypotension • Shock, collapse • Orthostatic hypotension

Figure 87.3 Ultrasound image of a caesarean scar ectopic pregnancy.

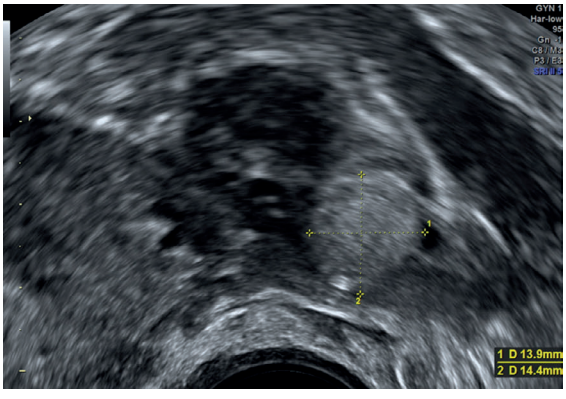

Figure 87.4 Ultrasound image of a tubal ectopic pregnancy.

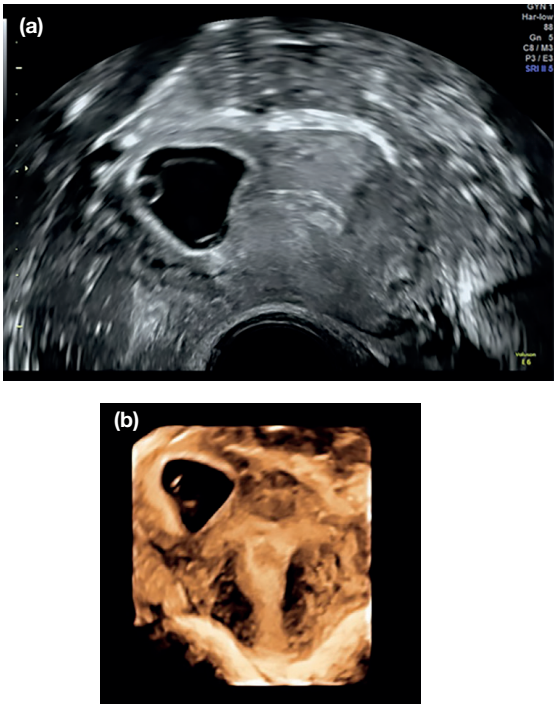

Figure 87.5 (a, b) Ultrasound images of an interstitial ectopic pregnancy.

Christian Johann Doppler, 1803–1853, Professor of Experimental Physics, Vienna, Austria, enunciated the 'Doppler principle' in 1842.

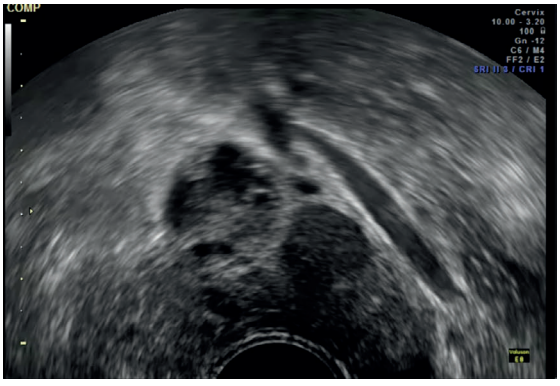

Figure 87.6 Ultrasound image of an ovarian ectopic pregnancy.

The presentation of an ectopic pregnancy is variable and the differential diagnoses include:

- miscarriage;
- urinary tract infection;
- ovarian cyst accident;
- appendicitis.

A transvaginal ultrasound scan should be performed if the diagnosis is suspected (see ***Table 87.1*** for the defining ultrasound characteristics of uterine and extrauterine ectopic pregnancies). The complete absence of an intrauterine gestational sac with a positive pregnancy test increases the probability of an ectopic pregnancy unless the pregnancy is not sufficiently advanced for the sac to be seen on ultrasound scan. An ectopic pregnancy is more likely if free fluid is seen in the pouch of Douglas or an adnexal mass is identified on ultrasound scan.

In equivocal cases, serial measurements of serum βHCG levels, 48 hours apart, can help to establish the diagnosis. A rise in the βHCG level by at least 63% is more indicative of a viable intrauterine pregnancy and an ultrasound scan should be offered between 7 and 14 days. Levels that halve when taken 48 hours apart are more suggestive of a failing pregnancy and a urinary pregnancy test should be repeated after 14 days. Levels that remain static or show a suboptimal increase or decrease over a 48-hour period are more likely to be representative of an ectopic pregnancy. Furthermore, a single level above approximately 1500 IU/L, in association with an empty uterus on ultrasound scan, in the absence of a heavy bleed, is suggestive of an ectopic pregnancy. Laparoscopy can also be used as a diagnostic tool (***Figure 87.7***); occasionally, however, a false-negative diagnosis is obtained when the pregnancy is not sufficiently advanced and is, therefore, too small to be seen within the fallopian tube.

Management of an ectopic pregnancy can be divided into expectant, medical (methotrexate) or surgical treatment. The choice of treatment is dependent on: the haemodynamic stability of the patient; ultrasound features of the ectopic pregnancy (presence of free fluid, presence or absence of fetal cardiac activity); serum βHCG level; and the patient's understanding of the diagnosis, commitment to follow-up and choice.

Expectant management and medical management in the form of methotrexate can be offered to women who are clinically stable and pain free, who have a serum βHCG level

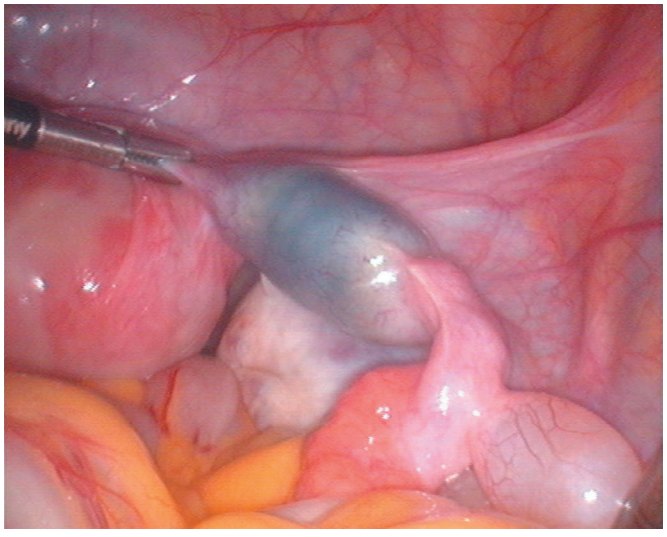

Figure 87.7 Laparoscopic image of a tubal ectopic pregnancy.

<1500 IU/L for expectant management and between 1500 and <5000 IU/L for medical management, who are committed to the follow-up protocol and where the ectopic pregnancy is not alive and measures <35 mm. In these circumstances, repeat serum βHCG levels are recommended on days 4 and 7. A fall of ≥15% is considered reassuring and should be repeated weekly thereafter until <20 IU/L. If the levels deviate from this, then the patient should be reviewed further to plan ongoing management. Women should be advised of the risk of rupture and the need for additional/alternative treatment if the situation should change.

Methotrexate is a folic acid antagonist that interferes with DNA synthesis. Significant side effects include hepatotoxicity. Further pregnancies should be avoided for a minimum of 3 months following treatment with methotrexate. Careful patient selection is vital. Furthermore, some patients fail to respond to this medication and will require surgical management.

Surgical management should be offered to women who prefer to have surgery or those who are unable to commit to follow-up as well as those with significant pain, those who have a rising serum βHCG level of ≥5000 IU/L and/or those in whom the ectopic pregnancy is considered to be live and measures ≥35 mm.

Surgical options include a salpingectomy (removal of the fallopian tube) or salpingostomy (opening of the fallopian tube and extraction of the pregnancy tissue) (***Figure 87.8***). This is ideally performed laparoscopically in a stable patient as it

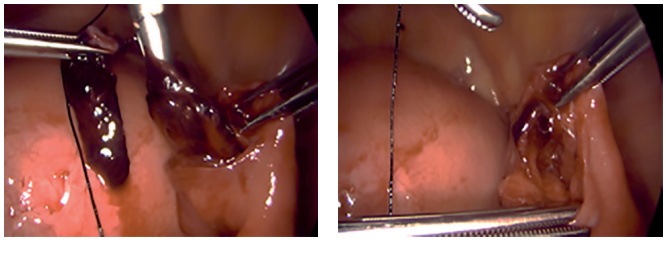

Figure 87.8 Laparoscopic salpingostomy.

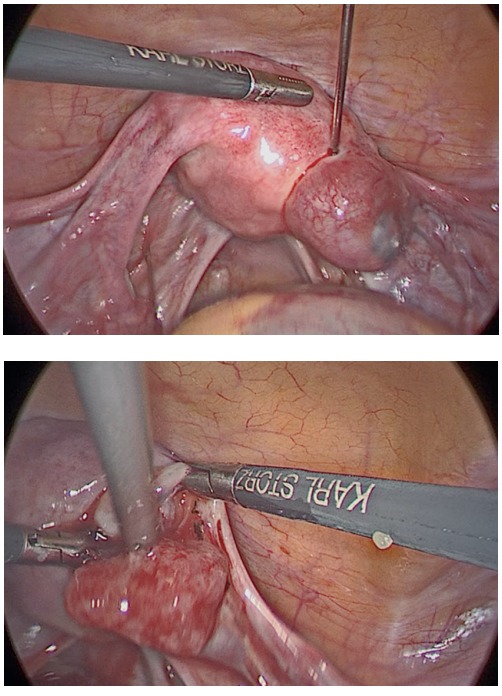

Figure 87.9 Laparoscopy of an interstitial ectopic pregnancy.

is associated with shorter operative times, less intraoperative blood loss, shorter hospital stays and similar subsequent intrauterine pregnancy rates. A laparotomy may be required if the woman is haemodynamically unstable. A salpingectomy is the preferred technique in the presence of a contralateral healthy fallopian tube. A salpingostomy is associated with an 8% risk of persistent trophoblastic tissue, intra-abdominal bleeding and an increased risk of a repeat ectopic pregnancy. These patients are subsequently followed up with serial serum βHCG levels until a negative result is obtained to exclude the presence of residual trophoblastic tissue. If a further ectopic pregnancy occurs within the same fallopian tube, then a salpingectomy is recommended regardless of the condition of the contralateral fallopian tube.

The management of non-tubal ectopic pregnancies (e.g. interstitial ectopic pregnancies [*Figure 87.9*], caesarean section scar ectopic pregnancies) can be complex and associated with more significant complications, such as bleeding, leading to an increased risk of a hysterectomy. These cases are best managed in tertiary centres. The management plan will be guided by the haemodynamic stability of the patient and the location of the ectopic pregnancy, including the expertise of the clinician managing the case.

These patients should be counselled regarding their increased risk of further ectopic pregnancies in subsequent conceptions. In view of this, they are encouraged to present as early as possible in any subsequent pregnancy to establish its location. Anti-D immunoglobin should be administered to non-sensitised rhesus (Rh)-negative women.

ACUTE ABDOMEN

Abdominal pain is one of the most challenging presenting complaints in the emergency department. Common causes of acute lower abdominal pain in the non-pregnant woman include:

- adnexal torsion;
- ovarian cyst accident, e.g. rupture;
- PID;
- endometriosis;
- appendicitis;
- bowel obstruction.

Adnexal torsion

An adnexal torsion is commonly the result of an ovary, and occasionally a fallopian tube, twisting along its pedicle and interrupting its arterial supply, leading to ischaemia. Rapid identification and intervention are necessary to preserve ovarian function. *Table 87.3* lists the presenting characteristics, recommended investigations and management options of an ovarian torsion.

TABLE 87.3 Presenting characteristics, recommended investigations and management options of an ovarian torsion.

Characteristics	
Symptoms and signs	• Abdominal pain (sudden onset) • Nausea/vomiting • Diarrhoea • Abdominal/pelvic tenderness • Palpable adnexal mass • Signs of peritonism • Non-specific and, therefore, a high clinical suspicion is necessary
Risk factors	• Enlarged ovary, e.g. cyst • Para-ovarian cyst • Hydrosalpinx • Previous torsion
Investigations	
Ultrasound	• Unilateral ovarian enlargement and ovarian tissue oedema, with less defined borders. Comparison with the contralateral ovary will show a distinct difference • Peripheral displacement of follicles; follicular ring sign • Central placement of the ovarian/adnexal mass in the suprapubic region • The affected ovary may appear as a solid mass with hypo- and hyperechoic areas, in keeping with haemorrhage and necrosis • The pedicle that is twisted may be seen as a 'whirlpool' that is visible both in grey-scale and on colour Doppler • Abnormal Doppler signals, e.g. coiling of the ovarian vessels (early/subacute), complete absence of perfusion (late) • Free fluid in the pelvis
Bloods	• Raised inflammatory markers (can also be normal)
Management	
Laparoscopy (*Figure 87.10*)	• Detorsion • Ovarian cystectomy to be performed at the same time or at a later date once the ovary is reperfused and the degree of oedema has diminished to reduce the likelihood of an oophorectomy

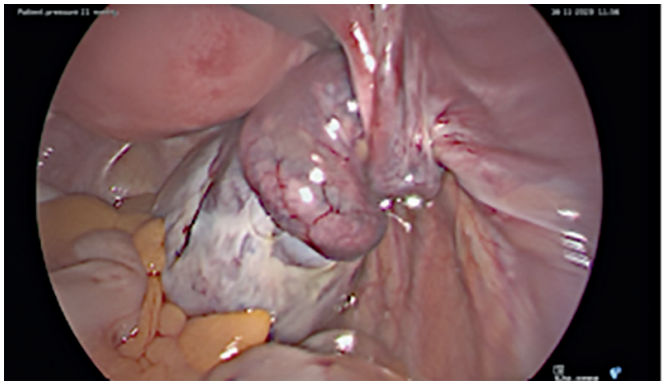

Figure 87.10 Laparoscopic image of ovarian torsion.

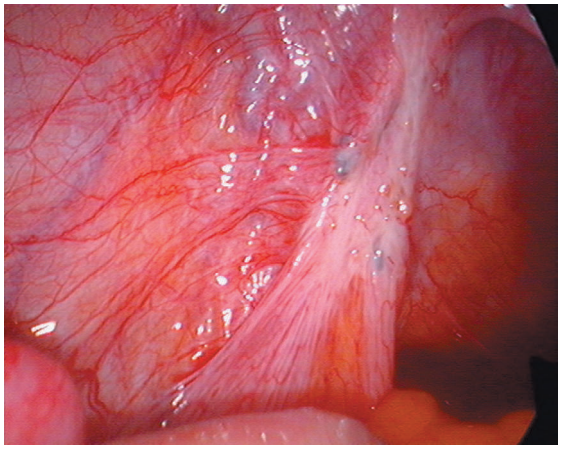

Figure 87.12 Endometriosis seen on the uterosacral ligament.

CHRONIC ABDOMINAL PAIN

Endometriosis

Endometriosis is a common inflammatory condition and is diagnosed by the presence of endometrium-like tissue in extrauterine sites. The most commonly affected sites are the pelvic organs and peritoneum, although distant sites such as the lungs are occasionally affected (resulting in symptoms such as recurrent haemoptysis at the time of menstruation or recurrent pneumothoraces) (***Figure 87.11***). The exact pathognomonic mechanism remains elusive, but it is widely believed that most endometriotic lesions develop from retrograde menstruation. It is estimated to affect 5–10% of women, mainly of reproductive age, with the incidence reported to be higher in certain subgroups, e.g. women with a history of infertility. Endometriosis may be associated with a number of symptoms, but the predictive value of any one symptom or set of symptoms remains uncertain as each can have other causes (e.g. irritable bowel syndrome or interstitial cystitis), with a significant proportion of affected women remaining asymptomatic. The most common symptom is pain. Other symptoms include: cyclical and non-cyclical pain; dysmenorrhoea (pain related to menstruation); deep dyspareunia (pain during intercourse); dyschezia (pain on opening the bowels); and dysuria. Many women also suffer from fatigue, haematuria, chronic pelvic pain, infertility and rectal bleeding (haematochezia).

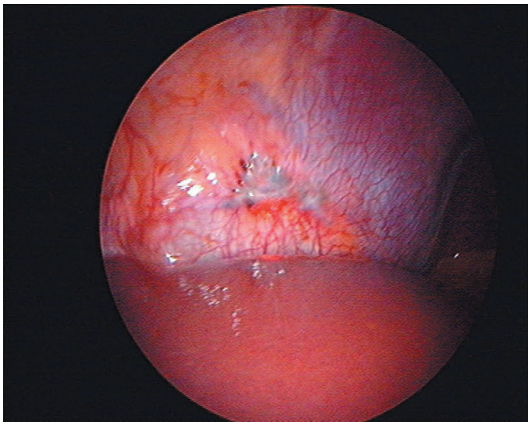

Figure 87.11 Endometriosis seen on the peritoneal surface of the diaphragm.

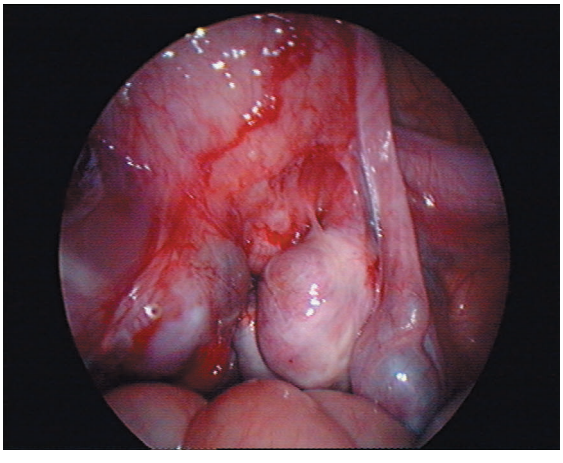

Figure 87.13 Bilateral ovarian endometriosis with pelvic adhesions.

The extent of the disease varies from a few small peritoneal lesions on otherwise normal pelvic organs to deep endometriosis and large ovarian endometriotic cysts (endometriomas). The identification of endometriomas has been synonymous with deep disease. There can be extensive fibrosis in structures such as the uterosacral ligaments (***Figure 87.12***), and adhesion formation causing marked distortion of the pelvic anatomy (***Figure 87.13***). Disease severity can be assessed by describing the operative findings, or quantitatively using various classification systems, but there is little correlation between such systems and the type or severity of symptoms experienced.

Endometriosis typically appears as superficial 'powder burn' or 'gunshot' lesions on the ovaries, serosal surfaces and peritoneum – black, dark brown or bluish puckered lesions, nodules or small cysts containing old haemorrhage surrounded by a variable extent of fibrosis. Atypical or 'subtle' lesions are also common, including red implants (petechial, vesicular, polypoid, haemorrhagic, red flame-like) and serous or clear vesicles. Other appearances include white plaques or scarring and yellow-brown discoloration of the peritoneum. Ovarian

endometriomas usually contain thick fluid-like tar and have been reported in 17–44% of women with endometriosis. They are distinguishable from simple haemorrhagic ovarian cysts because typically they are densely adherent to the peritoneum of the ovarian fossa, fallopian tube and posterolateral aspect of the uterus. The surrounding fibrosis may also involve the bowel. Deep endometriosis represents another disease type. This is defined by the presence of endometrium-like tissue 5 mm beneath the peritoneum, with growth seen in the uterosacral ligaments, vagina, bowel, bladder or ureters; when such lesions grow into the vagina they may be visible on speculum examination as 'blue-domed' cystic lesions in the posterior fornix. Lesions infiltrating the bowel may mimic cancer in their presentation.

The gold standard for making a diagnosis of endometriosis is through laparoscopy with histological confirmation; non-invasive diagnostic tools, such as ultrasound scanning (transvaginal and transrectal), can reliably detect only severe forms of the disease, i.e. endometriomas or deep endometriosis of the pelvis. MRI can detect haemosiderin deposits in abdominal organs to suggest deep endometriosis. A sigmoidoscopy may also provide additional information on the level of disease involvement in cases of deep endometriosis involving the bowel. The distance between the inferior border of a bowel lesion and anal verge can impact on the proposed surgical intervention and degree of associated risks. Excision of low rectal lesions (5–8 cm from the anal verge) has been associated with a higher risk of anastomotic leaks and transient neurogenic bladder dysfunction.

Finding pelvic tenderness, a fixed retroverted uterus, tender uterosacral ligaments or enlarged ovaries on examination is suggestive of endometriosis. The diagnosis is more certain if deeply infiltrating nodules are found on the uterosacral ligaments or in the pouch of Douglas and/or visible lesions are seen in the vagina or on the cervix. A digital rectal examination should also be conducted to assess for disease involving the rectosigmoid area, as well as lateral and dorsal extension of the disease suggesting involvement of the hypogastric vessels and/or nerves. The findings may, however, be normal.

The treatment options are limited because the cause is uncertain. These include: conservative management; medical management (simple analgesia or hormonal drugs to suppress ovarian function [progestogens, the levonorgestrel intrauterine system, gonadotropin-releasing hormone agonists in conjunction with add-back hormone replacement therapy]); and surgical management (ablation or excision of endometriotic lesions). Women may require multiple admissions for surgery and/or prolonged treatment with costly drugs that can have problematic side effects. Surgical planning needs to be aware of the proximity of the disease to the ureter and the risk of ureteric stricture leading to hydronephrosis and renal dysfunction. The surgical risks include those for any laparoscopic procedure, including damage to the bowel, bladder and ureters (2 in 1000 women); the risks are increased if deep endometriosis is present secondary to anatomical displacement of structures such as the ureter, as well as in repeat surgical cases where repeated ureterolysis can increase the risk of ureteral ischaemia and repeated bowel shavings can reduce the integrity of the bowel wall increasing the risk of fistula formation. Bowel resection or injury increases the risk of faecal peritonitis. Bowel integrity can be assessed by stretching the bowel over a rectal manipulator to identify thinned areas, filling the pelvis with fluid and then pushing air into the rectal lumen whilst looking for bubbles or injecting methylene blue in the rectum and looking for leaks. Consideration should be given to ureteral stent insertion in cases of bladder endometriosis close to the trigonum which can usually be removed after approximately 6 weeks. A catheter will be needed for 8–10 days postoperatively, followed by a cystogram checking for suture integrity prior to removal. Rarely, infection in an endometrioma will result in the formation of a tubo-ovarian abscess.

For a woman who has completed her family, hysterectomy plus bilateral salpingo-oophorectomy with total excision of endometriotic disease offers a good chance of cure. Surgical treatment, however, in a woman who wishes to retain her fertility needs to be as conservative as possible, ensuring that ovarian function is preserved. The aim is to remove the endometriotic tissue while restoring the pelvic anatomy. The preferential method to retain ovarian function is ovarian drainage with directed spot ablation (electrocoagulation, thermal coagulation, laser or plasma energy) over cystectomy. Counselling needs to include the increased risk of recurrence with cyst drainage versus a cystectomy, as well as consideration for preoperative oocyte cryopreservation, especially in the presence of bilateral ovarian disease. Furthermore, bowel shaving versus bowel resection is associated with the risk of incomplete disease resection.

Several classification and staging systems have been proposed for the diagnosis, management and prognosis of endometriosis. Currently, there is a need for an internationally accepted system. The endometriosis fertility index has demonstrated good predictive value in the determination of fecundity after endometriosis surgery. Endometriosis is also associated with an increased risk of ovarian cancer (endometrioid and clear-cell types) and non-Hodgkin's lymphoma, adding to the burden of the disease.

Adenomyosis

Adenomyosis is a benign uterine disorder characterised by the presence of ectopic endometrium or endometrium-like structures within the myometrium accompanied by smooth muscle hypertrophy or hyperplasia. The ectopic endometrium can be present either diffusely or focally within the myometrium. The complexity of the condition is contributed to by its variable presentation and difficulty in making an accurate diagnosis, and, subsequently, its management. The true prevalence of the condition is unknown because of variable diagnostic criteria, and ranges from 1% to 70%. ***Table 87.4*** outlines the presenting characteristics, recommended investigations and management options.

Thomas Hodgkin, 1798–1866, curator of the museum and demonstrator of morbid anatomy, Guy's Hospital, London, UK.

TABLE 87.4 Presenting characteristics, recommended investigations and management options for adenomyosis.

Presenting characteristics	
Symptoms	• Non-specific • Dysmenorrhoea • Abnormal uterine bleeding • Chronic pelvic pain • Subfertility • Presentation in the fourth and fifth decades of life • Asymptomatic • Dyspareunia
Signs	• Uterine enlargement • Uterine tenderness • Abnormalities identified at hysteroscopy (irregular endometrium with endometrial defects, cystic haemorrhagic lesions, altered vascularisation)
Risk factors	• Increased/longer oestrogen exposure (early menarche [≤10 years of age], short menstrual cycles [≤24 days in length], elevated body mass index, oral contraceptive use, increasing age, tamoxifen use) • Spontaneous miscarriage and multiple pregnancies • Increasing parity • Uterine instrumentation/incision (caesarean sections, surgical termination of pregnancy, SMM, endometrial curettage) • Endometrial hyperplasia • Leiomyomas that breach the endometrial–myometrial interface • Endometriosis • Smoking
Diagnosis	
Ultrasound	• The Morphological Uterus Sonographic Assessment (MUSA) group recommends commenting on eight morphological features in its classification of adenomyosis (presence, location, differentiation, cystic or non-cystic, myometrial layer, the extent of disease, size of the lesion and vascularity). Typical features include an enlarged globular uterus with asymmetrical thickening of the myometrium, myometrial cysts, echogenic subendometrial lesions, hyperechogenic islands, fan-shaped shadowing, an irregular junctional zone and vascularity on colour Doppler (*Figures 87.14–87.17*) • Three or more sonographic criteria are usually required to make a diagnosis of adenomyosis
Magnetic resonance imaging	• Can help differentiate an adenomyoma from fibroids
Histology	• Historically obtained at the time of hysterectomy; considered the gold standard • Limited in those wishing to preserve their fertility
Management	
Medical management	• Analgesia (i.e. NSAIDs) • Hormonal preparations (i.e. levonorgestrel IUS [off-label use]; combined oral contraceptive pill; progestogens, i.e. dienogest; GnRH agonists and antagonists; danazol; aromatase inhibitors, i.e. letrozole; selective progesterone receptor modulators)
Radiological interventions/ minimally invasive treatment options	• HIFU or MRgFUS: adverse effects include abdominal pain, skin burns and leg pain secondary to thermal injury of the sciatic nerve, intestinal perforation and temporary acute renal failure • UAE: postembolisation syndrome is reported, which consists of pelvic pain, nausea, fever secondary to necrosis and haematoma formation at the femoral artery puncture site. In addition, complications such as those associated with radiation exposure, haemorrhage, unplanned surgery, infections and an age-related impairment of ovarian reserve have also been reported
Surgical management (uterus preserving) (adenomyomectomy)	Different techniques: • Non-excisional surgical techniques (thermal coagulation of diseased myometrium) • Partial reduction surgeries (i.e. for diffuse adenomyosis including wedge resections, wedge-shaped uterine wall removal, modified reductive surgery and transverse H incisions) • Complete adenomyotic excision (i.e. for focal adenomyosis including the double- or triple-flap method and asymmetric dissection method)
Surgical management (non-uterine preserving)	• Hysterectomy: a total hysterectomy is preferred over a subtotal procedure as recurrence of the disease has been reported within the cervical stump and rectovaginal septum • Endometrial ablation/resection
Postoperative complications	• Uterine rupture (6% [>1% following an adenomyomectomy versus 0.26% following a myomectomy]), silent uterine rupture • Higher incidence of placenta accreta, increta and percreta compared with caesarean sections and myomectomies • Asherman's syndrome • Disease recurrence

GnRH, gonadotropin-releasing hormone; HIFU, high-intensity focused ultrasound; IUS, intrauterine system; MRgFUS, magnetic resonance-guided focused ultrasound; NSAID, non-steroidal anti-inflammatory drug; SMM, surgical management of miscarriage; UAE, uterine artery embolisation.

Joseph (Gustav) Asherman, 1889–1968, Czech–Israeli gynaecologist. This syndrome was first described by Heinrich Fritsch in 1894, Asherman further characterised it in 1948.

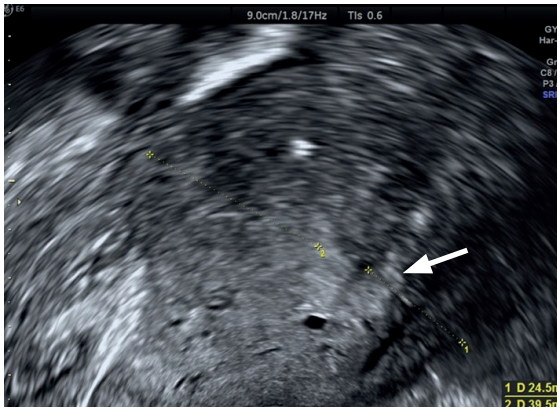

Figure 87.14 Ultrasound features of adenomyosis. Asymmetry between the anterior and posterior uterine wall and hyperechoic islands (arrow).

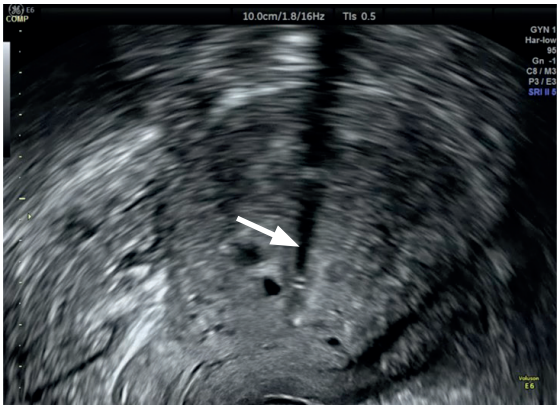

Figure 87.16 Ultrasound features of adenomyosis. Anechogenic myometrial tissue with acoustic shadowing posterior to it (arrow).

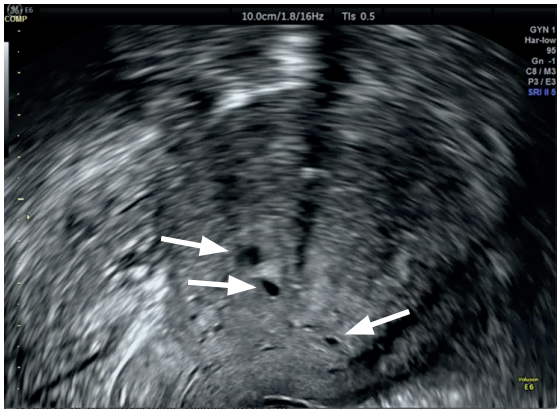

Figure 87.15 Ultrasound features of adenomyosis. Myometrial cysts (arrows).

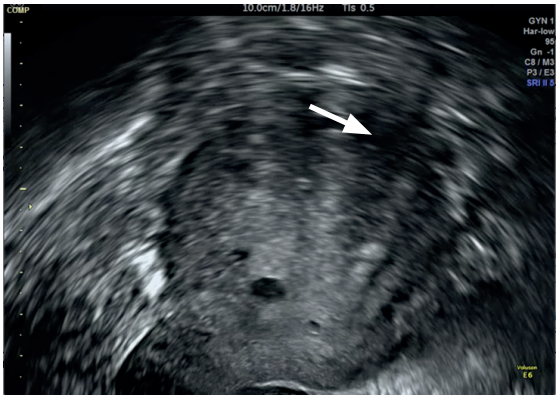

Figure 87.17 Ultrasound features of adenomyosis. Fan-shaped shadowing (arrow).

ABNORMAL UTERINE BLEEDING IN THE NON-PREGNANT STATE

Bleeding in the non-pregnant state may occur at the time of an expected menstrual period, between periods (intermenstrual bleeding; IMB), after intercourse (postcoital bleeding; PCB) or following the menopause (postmenopausal bleeding; PMB). Menopause is diagnosed in women who have not had a menstrual period after 12 months without the use of hormonal contraception. Vaginal bleeding may also occur after surgical instrumentation of the uterus and/or cervix, including insertion of an IUCD. The principal causes of uterine and vaginal bleeding in the non-pregnant state can be divided into structural and non-structural causes (***Table 87.5***) and their relationship to menses or coitus (***Table 87.6***).

The mainstay of management is to identify and treat the associated pathology. Investigations include a pregnancy test and ultrasound assessment of the pelvic anatomy (two-dimensional/three-dimensional ultrasound scan or saline sonogram) as well as an endometrial biopsy of the uterine cavity, performed either under direct vision at hysteroscopy or blindly with a Pipelle® biopsy. Hysteroscopy combined with endometrial biopsy improves the sensitivity and specificity for detection of endometrial pathology compared with either performed alone (***Figure 87.18***). The indications for undertaking an endometrial biopsy are shown in ***Summary box 87.2***. A colonoscopy may also be indicated to exclude colorectal pathology as a potential cause for the bleeding.

Women taking tamoxifen, a selective oestrogen receptor modulator used in the treatment of breast cancer, represent a special group as the drug can induce uterine abnormalities in 10–40% of women, such as the development of endometrial polyps, hyperplasia, cancer and, rarely, uterine sarcomas, which are much more aggressive. Tamoxifen treatment results in a doubling of the risk of endometrial cancer after 1–2 years and has a quadrupling effect after 5 years. The relationship is time dependent but dose independent. The risk does not decrease on cessation of treatment. There is no consensus regarding the need for screening and which method to use; the alternative, more common approach is to investigate only those women who develop abnormal uterine bleeding with tamoxifen use. Aromatase inhibitors such as anastrozole, letrozole and exemestane are also used in the treatment of breast cancer, but their effects are not mediated via the oestrogen receptor so they have been associated with less endometrial pathology than tamoxifen. They may also reverse abnormalities induced by tamoxifen use.

TABLE 87.5 Structural and non-structural causes of uterine and vaginal bleeding.

Structural	• Endometrial or endocervical polyp • Fibroids (leiomyoma) • Endometrial hyperplasia • Malignancy of the genital tract
	• Endometriosis • Adenomyosis • Coagulopathy, e.g. thrombocytopenia, von Willebrand's disease • Ovulatory dysfunction, e.g. polycystic ovary syndrome • Endometrial, e.g. endometritis • Iatrogenic, e.g. exogenous sex steroid administration, IUCD, hormonal contraceptive use • Other, e.g. arteriovenous malformations, chronic renal/hepatic disease

IUCD, intrauterine contraceptive device.

TABLE 87.6 Uterine and vaginal bleeding in the non-pregnant state in relation to menstrual bleeding.

Menstrual	• Endometrial polyp/malignancy[a] • Fibroids
Intermenstrual	• Vaginal trauma/malignancy[a] • Cervical polyp/malignancy • Endometrial polyp/malignancy[a]
Postcoital	• Vaginal malignancy[a] • Cervical ectropion/polyp/malignancy

[a]These cancers occur principally in postmenopausal women.

Summary box 87.2

Indications for an endometrial biopsy

Endometrial biopsy should be considered in the following cases:

- Women with suspected endometrial pathology
- All women >45 years old in whom medical treatment has been unsuccessful
- Women with persistent intermenstrual bleeding
- Endometrial thickness >4 mm in postmenopausal women or persistently thickened or abnormal appearance of the endometrium in premenopausal women and endometrial thickness >7 mm in women with known polycystic ovarian syndrome
- Irregular or unscheduled bleeding while on hormone replacement therapy after the initial 3 months
- Younger women with major risk factors for endometrial hyperplasia/cancer:
  - Polycystic ovarian syndrome
  - Obesity
  - Treatment with tamoxifen
- Irregular bleeding while on unopposed oestrogen
- Irregular bleeding in high-risk populations, such as family history of endometrial/colon cancer, especially hereditary non-polyposis colorectal cancer

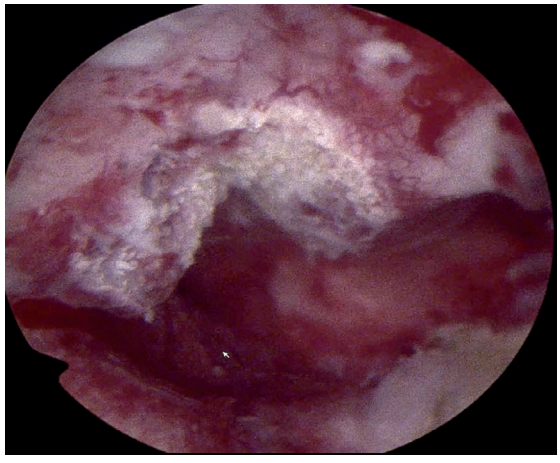

Figure 87.18 Hysteroscopic biopsy of endometrial cancer (cystic endometrium is visible at hysteroscopy).

Women known to have Lynch syndrome (hereditary non-polyposis colorectal cancer) and those considered at risk of inheriting a mismatch repair gene abnormality are another special group, as their lifetime risk of developing endometrial cancer is as high as 60%. Unlike sporadic cases of endometrial cancer, which are usually diagnosed during the sixth and seventh decades, the mean age at diagnosis in Lynch syndrome is the fifth decade. However, it appears that the 5-year survival rate in patients with Lynch syndrome-associated endometrial cancer is similar to that in women with sporadic disease. International guidelines suggest that these women should be screened annually from the age of 35 years with transvaginal ultrasound to measure the endometrial thickness and an endometrial biopsy.

Abnormal bleeding can also be caused by invasive carcinoma of the cervix, the incidence of which has been reduced by screening programmes that aim to detect the precancerous state, cervical intraepithelial neoplasia (CIN), using cervical cytology. The sample is checked for high-risk serotypes of human papillomavirus (HPV) (16, 18, 31 and 33) that can cause changes to the cervical cells. If these types of HPV are not identified on the sample, then no further action is required. If, however, these high-risk HPV serotypes are identified, the sample is checked for cervical cell changes, with the aim of treating these before they get a chance to turn into cervical cancer. In the UK, this is carried out every 3 years in women aged 25–49 years, and every 5 years in women aged 50–64 years. In women aged 65 years or older, a cervical screen will be conducted if one of the last three tests was abnormal or no test had been performed since the age of 50 years. Abnormalities in cervical cytology are followed up by microscopic examination of the cervix (colposcopy). CIN may be treated with local ablation (cryocautery, cold coagulation, electrocoagulation or laser) or excision (large loop excision of the transformation zone [LLETZ]).

Erik Adolf von Willebrand, 1870–1949, physician, Helsinki, Finland.
Henry T Lynch, 1928–2019, Professor of Preventative Medicine, Creighton University, Omaha, NE, USA, discovered familial susceptibility to certain kinds of cancer.

TABLE 87.7 Investigation and management of heavy menstrual bleeding.

Investigations	
Radiological imaging	TVUS has high sensitivity and specificity; MRI may be indicated if the women declines a TVUS or the findings are unclear. Identification of potential pathology such as polyps, fibroids
Hysteroscopy and histology	Direct visualisation of pathology with guided samples taken for histopathology
Management	
Medical management	• Tranexamic acid, NSAIDs (off-label use) • Oestrogen suppression with hormonal treatments (i.e. levonorgestrel IUS [after 1 year of use, there is a 71–95% reduction in menstrual blood loss with approximately 50% of women becoming amenorrhoeic], combined oral contraceptive pill [off-label use], progestogens, i.e. desogestrel [off-label use], GnRH agonists with or without add-back hormone replacement therapy) • GnRH agonists aim to shrink fibroids by inducing a hypo-oestrogenic state. This class of drug, however, is limited by its association with a loss in bone mineral density; in addition, fibroids tend to regrow to their original size when treatment is discontinued • Ulipristal acetate (Esmya®), an SPRM, is only licensed for use in premenopausal women in whom surgical procedures (including uterine fibroid embolisation) are not appropriate or have not worked. This drug should be used with caution as it has been associated with severe liver injury and liver function should be monitored during its use
Radiological interventions/minimally invasive treatment options	• HIFU or MRgFUS: adverse effects include abdominal pain, skin burns and leg pain secondary to thermal injury of the sciatic nerve, intestinal perforation and temporary acute renal failure • UAE involves blocking the blood supply to the fibroids using a technique in which particles are embolised into each uterine artery via an angiographic catheter (*Figure 87.19*). This technique has shown more value in the presence of a single large fibroid than in a multifibroid uterus. Postembolisation syndrome is reported, which consists of pelvic pain as a result of uterine ischaemia, nausea, fever secondary to necrosis and haematoma formation at the femoral artery puncture site. In addition, complications such as those associated with radiation exposure, haemorrhage, unplanned surgery, infection, thrombosis and an age-related impairment of ovarian reserve have also been reported
Surgical management (uterus preserving)	• Hysteroscopic polypectomy (risks include uterine perforation; damage to surrounding organs) • Transcervical resection of fibroids (complications include hyponatraemic fluid overload and thermal injury to surrounding structures) • Myomectomy (open or laparoscopic [*Figure 87.20*]). Surgical complications include bleeding and damage to surrounding structures, with the risk of conversion to a hysterectomy <1% secondary to excessive bleeding. Morcellation is described in further detail in *Uterine fibroids (leiomyoma)*
Surgical management (non-uterine preserving)	• Endometrial ablation/resection (risks include thermal injury to surrounding organs and fluid overload; not recommended in women wishing to retain their fertility). The aim of ablative methods is to reduce the menstrual bleeding by ablating the endometrium down to the basalis layer using electrical, thermal or laser energy. More than 90% of women report a reduction in menstrual blood loss without the need for further treatment at 2 years of follow-up, with 25–35% experiencing amenorrhoea. The criteria for endometrial ablation are described in *Table 87.8* • Hysterectomy: a total hysterectomy is preferred over a subtotal procedure as persistence of symptoms is reported within the cervical stump (risks include damage to surrounding organs and fistula formation)

GnRH, gonadotropin-releasing hormone; HIFU, high-intensity focused ultrasound; IUS, intrauterine system; MRgFUS, magnetic resonance-guided focused ultrasound; MRI, magnetic resonance imaging; NSAID, non-steroidal anti-inflammatory drug; SPRM, selective progesterone receptor modulator; TVUS, transvaginal ultrasound scan; UAE, uterine artery embolisation.

Cervical cancer is one of the leading causes of mortality in the world. To improve the uptake of the cervical screening programme, testing for HPV in the comfort of a woman's own home is being investigated.

Current vaccination programmes against HPV serotypes are aimed at reducing the incidence of cervical carcinoma. In the UK, the vaccination is currently offered to girls and boys aged 12–13 years with a repeat dose offered 6–24 months later, prior to becoming sexually active. The vaccine helps protect against mouth, throat, anal and genital cancers as well cervical cancer.

Menstrual bleeding may be excessively heavy, irregular or frequent in the absence of pathology; this is known as dysfunctional uterine bleeding. NICE guidance in the UK has suggested a three-step hierarchal treatment approach to the management of heavy menstrual bleeding (*Table 87.7*).

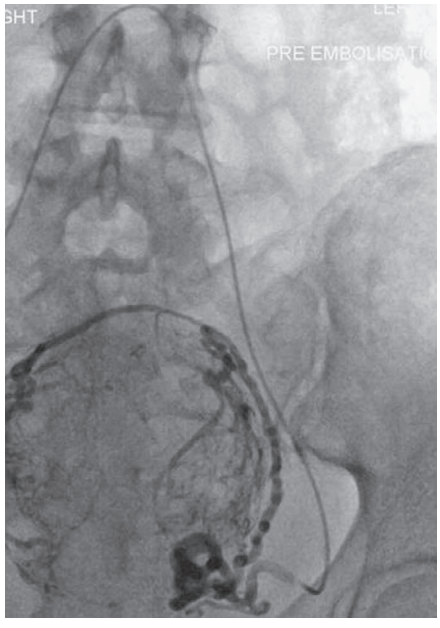

Figure 87.19 Pre-embolisation angiogram showing catheterisation of the left uterine artery and blood supply to a large fundal fibroid (courtesy of Dr Mark Bratby, Consultant Vascular and Interventional Radiologist, John Radcliffe Hospital, Oxford, UK).

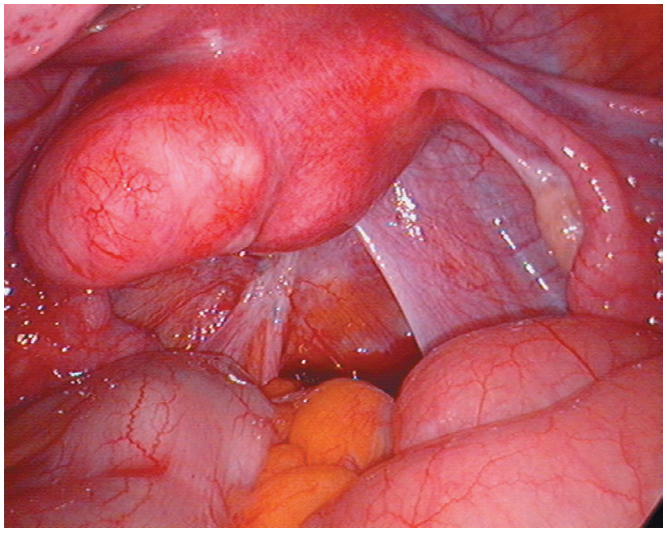

Figure 87.20 Laparoscopic view of a uterine fundal fibroid.

TABLE 87.8 Criteria for endometrial ablation.

- Uterus <10 cm in length
- Absence of major intrauterine pathology that would distort the uterine cavity
- No history of previous endometrial ablation procedures
- No evidence of endometritis
- Family is complete

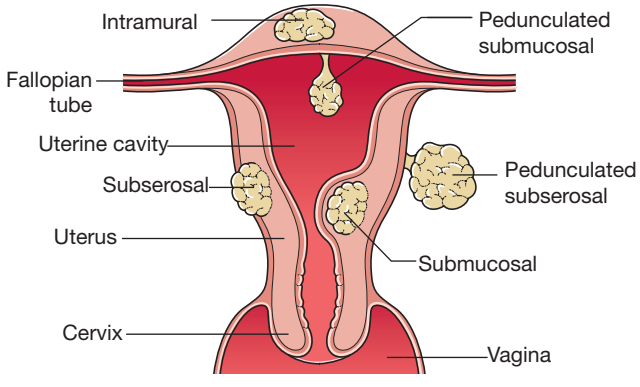

Figure 87.21 Uterine fibroids.

The management plans are individualised for the patient, taking into account concomitant symptoms and fertility requirements.

A hysterectomy can be carried out by three different routes: vaginally, abdominally or laparoscopically. The route of entry is dependent on a number of factors, including: uterine size; presence of other pathology; mobility and descent of the uterus; history of previous surgery; and skill of the operating surgeon. No difference in prolapse symptoms, sexual satisfaction or pelvic pain has been reported between a total or subtotal (conservation of the cervix) hysterectomy. Furthermore, it is now recommended that the fallopian tubes are removed in conjunction with the uterine body, whether the ovaries are conserved or not. The fallopian tubes have no continued functionality following a hysterectomy but can be a potential source of malignancy if retained. Conservation or removal of the ovaries is dependent on the woman's age, presence of coexisting pathology and/or risk factors for malignancy.

Uterine fibroids (leiomyoma)

Fibroids are usually benign, well-circumscribed, smooth muscle tumours of the uterus. Less than 1% of fibroids undergo malignant transformation (leiomyosarcoma). They are more common in certain populations (African–Caribbean women) and vary in size and number. They are typically found in the following locations (***Figure 87.21***):

- Subserosal: may cause pressure-type symptoms; if pedunculated, they can be difficult to distinguish from an ovarian tumour.
- Intramural: may similarly cause pressure-type symptoms; can be associated with infertility and heavy periods if they lead to endometrial distortion.
- Submucosal: associated with infertility, recurrent pregnancy loss and heavy periods; if pedunculated, they may occasionally extrude through the cervical os.
- Rare: sites include the broad ligament and cervix.

Women with uterine fibroids may present with heavy and/or irregular menstrual bleeding, anaemia, pressure-type symptoms or infertility, especially if the fibroid is distorting the uterine cavity. The pressure-type symptoms can include pelvic discomfort, urinary incontinence, frequency and retention, constipation and backache. When large fibroids are present, back pressure may cause or exacerbate varicosities. Although these symptoms are common, it is important to note that some women with fibroids are asymptomatic. Rarely, women may present acutely with pain arising from torsion of a pedunculated fibroid or red degeneration, especially in pregnancy.

A diagnosis can usually be made on bimanual and/or abdominal examination, in the presence of an enlarged uterus with attached swellings. The principal differential diagnosis is an ovarian tumour; in general, if an ovarian tumour is present, the uterus is felt separately on vaginal examination, although not if the structures are adherent to each other. A pelvic ultrasound scan is the first-line investigation with high sensitivity and specificity. An MRI can be performed if an ultrasound is declined by the patient or is inconclusive (***Figure 87.22***).

Treatment can be divided into: conservative if the woman is asymptomatic; medical to reduce the quantity of menstrual bleeding; hormonal manipulation to control menstrual bleeding or to shrink the fibroids; or surgical (uterus-preserving or non-uterus-preserving methodologies) (***Table 87.7***). The choice of treatment depends upon the woman's age and fertility intentions, the size and number of fibroids as well as their location. Emergency surgical treatment is only required if there is substantial menstrual bleeding or uncontrollable pain; these are rare events.

Morcellation

This is the process whereby larger tissue is broken down into smaller pieces, facilitating their removal through smaller incisions in the abdomen. In gynaecology, this is usually offered in the context of a laparoscopic myomectomy to remove fibroids or a laparoscopic subtotal hysterectomy to remove the body of the uterus. This procedure is undertaken with an instrument called a morcellator. The risks associated with morcellation include parasitic spread of tissue where the cut tissue deposits itself elsewhere and grows (1:120 to 1:1200) and the upstaging of previously undiagnosed malignancies (noting that this is also considered a risk during an open myomectomy if the fibroid capsule is breached), as well as missed malignancies owing to lost anatomy. Retrieval bags have been proposed to prevent dissemination of the tissue but the evidence regarding their use is currently awaited. In view of this, careful case selection is important. The risk of an uterine sarcoma increases as age increases, in the perimenopausal and postmenopausal stages of life, in the presence of *BRCA* mutations and Lynch syndrome, and in the context of rapidly growing fibroids non-responsive to oestrogen deprivation.

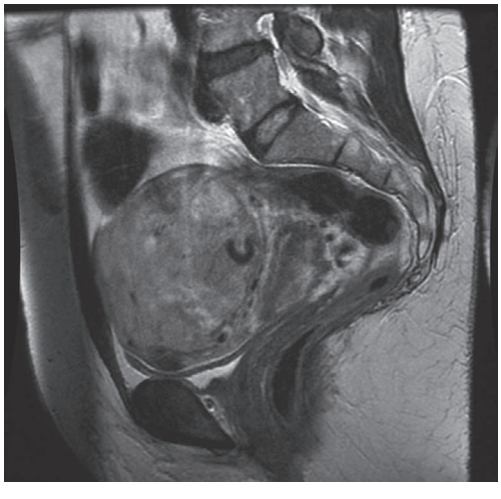

Figure 87.22 Magnetic resonance imaging of uterine fibroids.

UROGYNAECOLOGY

Urinary incontinence

Urinary incontinence is defined as the involuntary leakage of urine. It is said to affect approximately 30% of women, with a higher prevalence seen in older age groups. It can have a significant impact on quality of life.

Incontinence can be classified into:

- stress urinary incontinence (SUI) (involuntary leakage of urine secondary to increased intra-abdominal pressure, e.g. coughing, sneezing);
- overactive bladder (OAB); urinary urgency, usually with urinary frequency and nocturia, with or without urinary incontinence;
- mixed urinary incontinence (combination of both OAB and SUI).

It can result from both functional and anatomical causes, including:

- multiparity;
- childbirth complications and vaginal delivery;
- risng female age - menopause;
- fistulae;
- urethral diverticulum/congenital anomalies, e.g. ectopic ureters;
- immobility, constipation or urinary tract infection;
- chronic medical conditions, e.g. congestive heart failure, diabetes mellitus, multiple sclerosis;
- medications, e.g. loop diuretics;
- secondary to pelvic masses;
- obesity and weight gain.

Common symptoms and complaints include:

- storage symptoms:
  - frequency (increased frequency of more than eight times during the day)
  - urgency
  - nocturia (increased frequency of voiding more than once a night)
- emptying symptoms:
  - hesitancy
  - slow stream
  - incomplete emptying
  - straining to urinate
- urinary leakage with exertion/coughing

- haematuria (in women >40 years of age, additional investigations should be performed to rule out malignancy).

Investigations include:

- urinary incontinence-specific symptom and quality of life questionnaire, including a bladder diary;
- digital examination;
- urine analysis and a midstream urine sample for microscopy, culture and sensitivity;
- urodynamics, including an assessment of postvoid residual volumes – if conservative measures have failed, the type of incontinence is unclear or there is a recurrence of symptoms following surgical intervention;
- ultrasound of the kidneys, ureters and bladder in patients with recurrent urinary tract infections/haematuria;
- cystoscopy if pathology is suspected.

Management can be divided into conservative methods, medical therapy or surgical intervention (***Tables 87.9–87.11***). The treatment of choice is dependent on the underlying cause.

Treatments can be combined and are individualised for the patient. Should initial therapy be unsuccessful or repeat procedures be required, then the patients should be discussed within a multidisciplinary team (MDT) setting.

TABLE 87.9 Management options for overactive bladder (OAB).

Conservative	• Lifestyle changes (i.e. limit fluid intake, avoid diuretics such as tea/coffee, weight loss) • Behavioural modification (e.g. bladder drills) for a minimum of 6 weeks • Review of coexistent medications (e.g. diuretics) • Pelvic floor training (physiotherapy) for at least 3 months, comprising at least eight contractions three times per day • Bladder catheterisation-intermittent self catheterisation if increased post void residuals
Medical therapy	• Anticholinergics (e.g. oxybutynin [avoid in elderly frail women at risk of cognitive impairment], tolterodine); side effects include a dry mouth and constipation • Selective β_3-adrenoreceptor agonist (e.g. mirabegron) for the management of urge incontinence • Desmopressin specifically used to treat symptoms of nocturia
Surgical	• Intravesical botulinum toxin A • Neuromodulation (tibial nerve stimulation or sacral neuromodulation) • Bladder reconstruction (augmentation cystoplasty – risks include bowel disturbance, metabolic acidosis, mucus production and/or retention in the bladder, urinary tract infection, urinary retention and malignancy) • Urinary diversion only when non-surgical management has failed and if botulinum toxin type A, percutaneous sacral nerve stimulation and augmentation cystoplasty are not appropriate or are unacceptable

TABLE 87.10 Management options for stress urinary incontinence (SUI).

Conservative	• Pelvic floor training (physiotherapy) for at least 3 months, comprising at least eight contractions three times per day • Management of a persistent cough • Bladder catheterisation-intermittent self catheterisation if increased post void residuals
Medical therapy	• Serotonin and noradrenaline (norepinephrine) reuptake inhibitors (e.g. duloxetine) (can be used when conservative measures have failed and surgical treatment is contraindicated or declined)
Surgical	• Colposuspension (bladder neck suspension) • Autologous rectus fascial sling procedures and retropubic midurethral mesh slings • Periurethral bulking agents • Artificial urinary sphincter • Do not offer: anterior colporrhaphy; needle suspension; paravaginal defect repair; porcine dermis sling; the Marshall–Marchetti–Krantz procedure

TABLE 87.11 Management options for specific conditions causing urinary incontinence.

Pelvic masses	• Surgical approach, e.g. myomectomy or hysterectomy
Recurrent urinary tract infections	• Antibiotics – treatment, low dose prophylaxis, rescue course • 3 month course of vaginal oestrogen in post menopausal women
Fistulae or ectopic ureters	• Surgical correction

Uterovaginal prolapse

Pelvic organ prolapse refers to the protrusion or displacement of the pelvic organs from their normal anatomical position into or through the vagina to varying degrees (***Figure 87.23***). It is said to affect up to 40% of women at some point in their lifetime. A prolapse can have a detrimental impact on normal organ performance, including anorectal, urinary and sexual function.

A prolapse is more common in certain groups, including:

- older women;
- parous women, increased parity, prolonged labours, vaginal deliveries;
- obese women;
- women who have chronic constipation;
- women with occupations that involve heavy lifting;
- women with oestrogen deficiency;
- women with a family history or genetic risk;
- women with connective tissue disorders, e.g. Ehlers–Danlos syndrome, Marfan syndrome.

Edvard Laurits Ehlers, 1863–1937, dermatologist, Copenhagen, Denmark.
Henri-Alexandre Danlos, 1844–1912, dermatologist, Paris, France.
Antoine Bernard-Jean Marfan, 1858–1942, paediatrician, Paris, France.

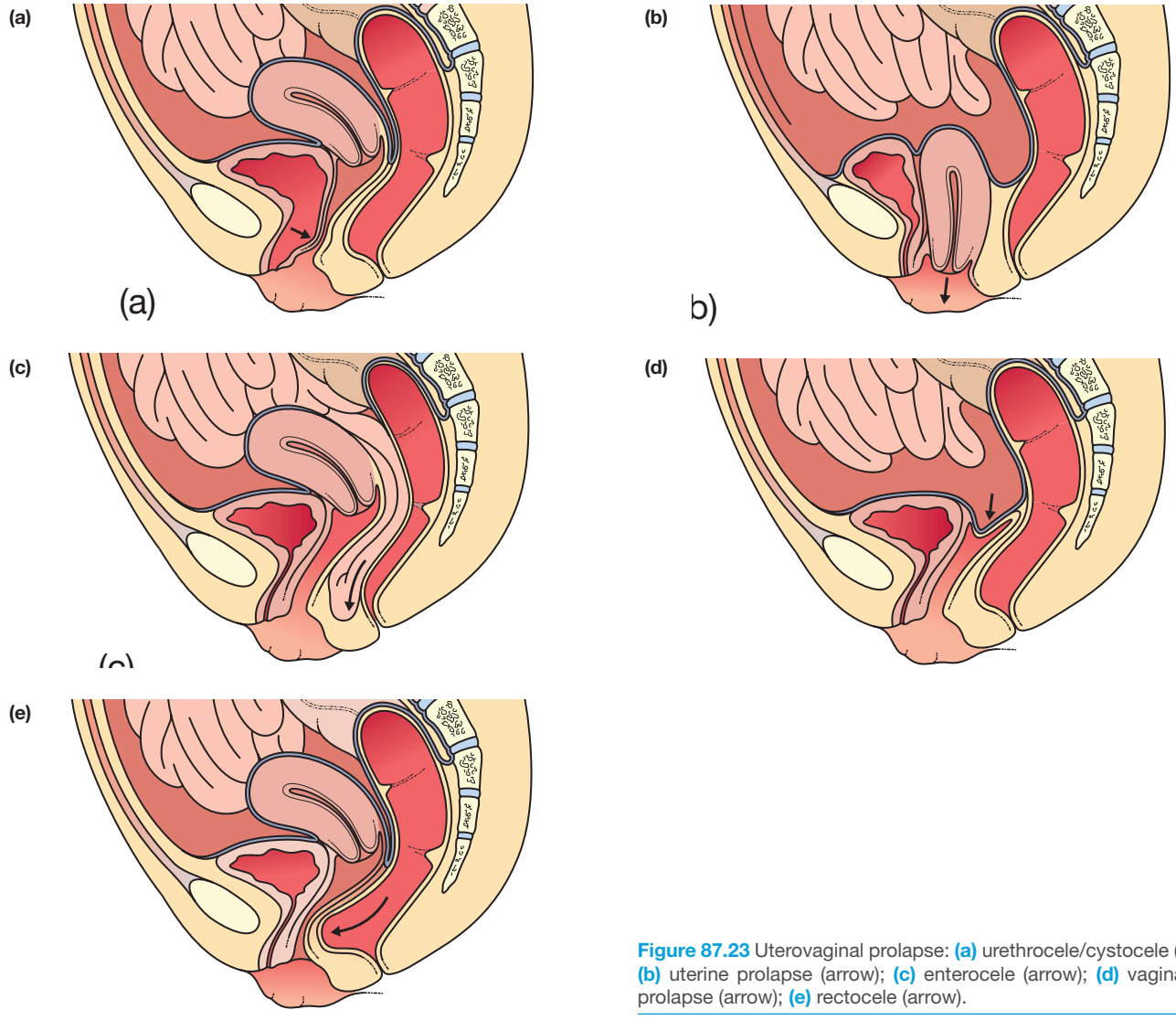

Figure 87.23 Uterovaginal prolapse: **(a)** urethrocele/cystocele (arrow); **(b)** uterine prolapse (arrow); **(c)** enterocele (arrow); **(d)** vaginal vault prolapse (arrow); **(e)** rectocele (arrow).

Women with minor prolapses may be asymptomatic, but those with more significant degrees may present with a sensation of 'something coming down'. A cystocele (bladder prolapse) and a cystourethrocele (prolapse of the bladder and urethra) can lead to the sensation of a lump in the vagina and may be associated with urinary urgency (OAB symptoms) and recurrent urinary tract infections. Uterine descent can lead to a lump in the vagina or a dragging sensation; with complete prolapse of the uterus (procidentia) there may be associated vaginal discharge, ulceration of the vaginal mucosa and bleeding. A rectocele (prolapse of the rectum into the vagina) may cause difficulties with defecation or a sensation of incomplete emptying, which can be relieved by digital reduction of the prolapse.

The degree of prolapse is graded in terms of descent. Currently, the commonly used grading system is the Pelvic Organ Prolapse Quantification System (POP-Q):

- grade 0: no prolapse is demonstrated;
- grade 1: the most distal portion of the prolapse is >1 cm above the level of the hymen;
- grade 2: the most distal portion of the prolapse is ≤1 cm above or below the level of the hymen;
- grade 3: the most distal portion of the prolapse is >1 cm below the level of the hymen but 2 cm less than the total vaginal length;
- grade 4: maximal descent.

Non-surgical management of a uterovaginal prolapse includes: lifestyle changes (avoidance of constipation); physiotherapy to help strengthen the pelvic floor muscles for at least 16 weeks for those with grade 1 or 2 organ prolapse; topical oestrogen replacement for oestrogen deficiency to help increase tissue strength and elasticity; and vaginal pessaries. There are a number of different pessaries available and they are replaced every 3–6 months, with the ring pessary being the most frequently used. It is inserted between the posterior fornix and the pubic bone. The main complications are of vaginal ulceration and infection leading to discharge and bleeding; it is advisable, therefore, to replace the ring frequently.

Surgical management aims to correct the prolapse. The surgical procedures are intended to restore the uterovaginal anatomy and position. They may be carried out using a vaginal or abdominal (open or laparoscopic) approach (*Table 87.12*).

TABLE 87.12 Surgical treatments for uterovaginal prolapse.

Condition	Treatment	Complications
Urethrocele/cystocele (*Figure 87.23a)*	• An anterior vaginal wall repair (anterior colporrhaphy) without the use of mesh	• Bleeding • Infection • Fistula formation • Voiding dysfunction • Unmasking of occult SUI • Failure • Recurrence
Uterine prolapse (*Figure 87.23b*)	• If the patient's family is complete, a vaginal hysterectomy with or without vaginal sacrospinous fixation can be performed • Uterus-preserving surgery includes: amputation of the cervix with suturing of the transverse cervical ligaments vaginally (Manchester repair); laparoscopic plication of the uterosacral ligaments (McCall suture); or hysteropexy, which may be vaginal (attaching the cervix to the sacrospinous ligaments using non-absorbable sutures) or laparoscopic/abdominal (sacrohysteropexy using a polypropylene mesh to suspend the uterus to the sacral promontory) • A colpocleisis can be considered in women who no longer wish to have penetrative intercourse	• Bleeding • Infection • Injury to the bladder, bowel or ureters • Voiding dysfunction • Dyspareunia • Failure • Recurrence • Conversion to a laparotomy • A Manchester repair can specifically be associated with infertility, miscarriage and dystocia
Enterocele (*Figure 87.23c*)	• A similar technique to repair of a hernia is used. The vaginal mucosa is opened and the hernial sac repaired	• Bleeding • Infection • Rectal or small bowel injury (fistula formation) • Dyspareunia • Failure • Recurrence
Vaginal vault prolapse (*Figure 87.23d*)	• Sacrospinous fixation performed vaginally: the vault is attached to the right sacrospinous ligament using a non-absorbable suture/mesh, avoiding the rectosigmoid colon on the left • Sacrocolpopexy performed abdominally or laparoscopically: the vaginal vault is attached to the sacral promontory using a mesh • A colpocleisis can be considered in women who no longer wish to have penetrative intercourse	• Bleeding • Infection • Injury to the bowel or ureter • Unmasking of occult SUI • Right buttock pain • Sexual dysfunction
Rectocele (*Figure 87.23e*)	• Posterior colpoperineorrhaphy without mesh: the posterior vaginal wall is opened, the rectum returned to its normal position and redundant vaginal mucosa excised	• Bleeding • Infection • Rectal or small bowel injury (fistula formation) • Dyspareunia • Failure • Recurrence

SUI, stress urinary incontinence.

Approximately 30% of women in their lifetime report a recurrence of their symptoms following surgical treatment. This figure increases with subsequent procedures.

Mesh

In the UK, mesh-related surgery is considered to be a high-vigilance operation, whereby use of synthetic mesh to treat SUI or urogynaecological prolapse has been restricted nationally secondary to a number of safety concerns that have been raised:

- pain or sensory change in the back, abdomen, vagina, pelvis, leg, groin and/or perineum;
- vaginal problems, including discharge, bleeding, dyspareunia, penile trauma or pain in sexual partners;
- urinary problems, including recurrent infections, incontinence, retention, difficulty or pain during voiding;
- bowel problems, including difficulty or pain on defecation, faecal incontinence, rectal bleeding or passage of mucus.

In view of this, an MDT approach is recommended to manage complex pelvic floor dysfunction and mesh-related problems. For women with a confirmed mesh-related complication or unexplained symptoms after a mesh procedure, referral should be made to regional centres specialising in the diagnosis and management of mesh-related complications. Continence surgery requiring mesh usage such as transvaginal tapes and

The **Manchester repair** was introduced at St Mary's Hospital for Women and Children, Manchester, UK.
Milton Lawrence McCall, 1911–1963, obstetrician, Magee-Women's Hospital, Pittsburgh, PA, USA.

transobturator tapes has been replaced by open/laparoscopic continence surgery in the form of colposuspension or insertion of an autologous fascial sling. Uterine prolapse and vaginal vault prolapse surgery requiring the use of mesh during hysteropexy and sacrocolpopexy procedures can be undertaken following detailed counselling and MDT agreement.

TUMOURS

Benign ovarian tumours and cysts

Overall, 90% of ovarian tumours are benign, with an increased risk of malignancy in older women: the malignant potential of an ovarian cyst in a premenopausal woman is 1:1000, increasing to 3:1000 at the age of 50 years. Ovarian tumours are subdivided into five main categories according to the World Health Organization's classification system (*Table 87.13*).

TABLE 87.13 Classification of ovarian tumours.

Surface epithelial tumours	• Represent approximately 65% of all ovarian tumours and 90% of ovarian malignancies • Further classified by cell type (serous, mucinous, endometrioid, clear cell, transitional cell, epithelial–stromal [undifferentiated]) and atypia (benign, borderline or malignant)
Germ cell tumours	• Represent approximately 15% of all ovarian neoplasms • Mature teratomas are the most common type of ovarian germ cell tumour (benign), often called a dermoid cyst. They most commonly occur in women of reproductive age and contain a variety of tissues, including skin, hair follicles, sweat glands, bone and teeth • Malignant germ cell tumours include immature teratomas, dysgerminomas, yolk sac tumours, choriocarcinomas and embryonal carcinomas
Sex cord–stromal tumours	• Represent approximately 10% of all ovarian neoplasms
Metastatic tumours	• Represent approximately 5% of ovarian malignancies; usually arise from breast, colon, endometrium, stomach and cervical cancers
Other/miscellaneous	• A small number of other types of neoplasms, which develop from ovarian soft tissue or non-neoplastic processes

Benign ovarian tumours are often asymptomatic and may present incidentally, for example when an abdominal radiograph reveals the appearance of a tooth in the abdomen or pelvis. Conversely, they may present with pain, abdominal swelling, pressure-type symptoms, nausea or vomiting. Sudden-onset pain with vomiting and raised inflammatory markers can be more diagnostic of ovarian torsion (see *Adnexal torsion*).

Management will depend on the age of the woman and the characteristics of the cyst (*Summary box 87.3*). In older women, a conservative approach is only reasonable if the risk of malignancy is low (see *Ovarian cancer*). In perimenopausal women, the cyst can be followed by serial ultrasound scanning as many will regress. If there is uncontrollable pain, haemodynamic compromise, suspicion of torsion or the cyst does not regress, then surgical management is advised. In most cases this would involve a laparoscopic ovarian cystectomy with conservation of ovarian tissue as the treatment of choice. As the vast majority of oocytes lie within 5 mm of the surface of the ovary, a carefully carried out cystectomy can leave a normally functioning ovary (*Figure 87.24*).

Summary box 87.3

Management of benign ovarian cysts

- Commonly, an incidental finding, but may be suggested by symptoms and signs
- A pregnancy test should be performed to exclude an ectopic pregnancy (however, it is important to note that HCG can also be positive in dysgerminomas and choriocarcinomas)
- TVUS is the mainstay diagnostic tool with high sensitivity and specificity in being able to differentiate a benign mass from a malignant one (*Table 87.14*). If the results are indeterminate, an MRI or CT scan may help; an MRI is more useful than a CT scan for the assessment of complex cysts/endometriosis. Masses with radiographic characteristics of cancer (e.g. cystic and solid components, surface excrescences, multilocular appearance, irregular shape) require removal
- Tumour markers may help in the diagnosis of specific masses (see *Ovarian cancer*)
- In women of reproductive age, simple, thin-walled cystic adnexal masses of a maximum diameter of 50 mm without characteristics of cancer do not require further investigation unless they persist for >3 months. A follow-up scan can be arranged after 4 months to check for resolution. In postmenopausal women, this is conducted every 4 months in conjunction with a serum blood test for the cancer antigen 125 (CA-125) for a duration of 1 year; if no change is detected, the women can be discharged
- Perimenopausal women with simple cysts measuring 50–70 mm in diameter should undergo annual ultrasound follow-up
- Women with larger cysts (>70 mm) or persistent cysts may benefit from an MRI scan or surgical intervention
- Cyst removal (ovarian cystectomy) is preferably performed laparoscopically. Cyst aspiration is associated with a high risk of recurrence but can be considered after detailed counselling if the woman wishes to retain her fertility. Bilateral salpingo-oophorectomy is preferable for postmenopausal women if surgery is indicated
- An oophorectomy may become necessary if the cyst cannot be surgically removed from the ovary

TABLE 87.14 International Ovarian Tumor Analysis (IOTA) group classification for the ultrasound assessment of ovarian cysts.

Benign features (B-rules)	Malignant features (M-rules)
• Unilocular cysts • Solid components, the largest of which is <7 mm • Acoustic shadowing • Smooth multilocular tumour <100 mm • No blood flow	• Irregular solid tumour • Ascites • Minimum of four papillary structures • Irregular multilocular tumour ≥100 mm • Blood flow

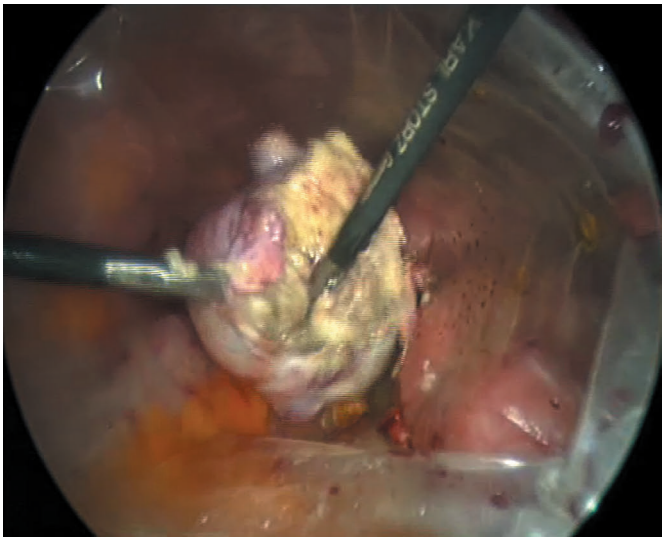

Figure 87.24 Ovarian cystectomy.

Ovarian cancer

Ovarian cancer is the sixth most common malignancy in women, behind breast, lung, bowel, uterine cancer and malignant melanoma. In the UK, over 7000 women are diagnosed with ovarian cancer each year. Over 90% of cancers arise from the surface epithelium of the ovary (which has the same embryological origins as the peritoneum); the majority arise sporadically rather than secondary to inheritance. The peak incidence is in the age range 65–69 years. The overall 5-year survival rate is <50% because approximately two-thirds of women present with advanced disease.

The common presenting symptoms are:

- abdominal distension and/or pain;
- change in appetite;
- weight gain and increased girth (ascites);
- urinary obstruction.

Over half of all women, however, present initially to a speciality other than gynaecology, with often vague symptoms caused by metastatic disease, e.g. shortness of breath, gastrointestinal disturbance or a change in bowel habit. Consequently, it is important to include ovarian cancer in the differential diagnosis of any woman presenting with a recent onset of persistent, non-specific, abdominal symptoms (including those whose abdomen and pelvis appear normal on clinical examination). A pelvic mass in conjunction with ascites usually indicates ovarian cancer but may also be indicative of Meigs' syndrome (a benign fibroma with ascites and the presence of a pleural effusion). ***Summary box 87.4*** addresses the basic tests that can be conducted to diagnose ovarian malignancy.

CA-125 is a glycoprotein expressed on tissue derived from coelomic and Müllerian epithelia; the normal cut-off value is 35 U/mL. Elevated levels are found in 50% of patients with stage I disease and >90% of those with advanced disease. It primarily detects epithelial ovarian cancers. However, CA-125 is a non-specific marker with raised levels also seen in other cancers, e.g. pancreatic, breast, lung and colon. Levels may also be increased during menstruation; in benign conditions such as endometriosis, PID and liver disease; if ascites or other effusions are present; and after a recent laparotomy. Combining menopausal status, ultrasound features and CA-125 measurements using the risk of malignancy index (RMI) algorithm (***Summary box 87.5***) can help guide management and identify those who require an onward referral to a gynaecological oncologist in a cancer centre.

Summary box 87.4

Basic tests on suspicion of ovarian malignancy

- Ultrasound scan is considered the first-line investigation (***Table 87.12***)
- A staging CT or MRI is carried out prior to surgery to determine the extent of disease
- Tumour markers, including βHCG, lactate dehydrogenase, alpha-fetoprotein (αFP), CA-125, CA-19-9 and carcinoembryonic antigen (CEA), should be measured. Lactate dehydrogenase, αFP, inhibin and βHCG are particularly recommended in women <40 years old with a suspected complex ovarian mass, to exclude germ cell tumours

Summary box 87.5

Risk of malignancy index (RMI)

- RMI = U × M × CA-125

  U, ultrasound features scoring 1 for each malignant feature (multilocular, solid components, metastases, ascites, bilateral lesions); M, menopausal status with 1 for premenopausal and 3 for postmenopausal; CA-125, CA-125 level in U/mL

There is currently no national screening programme for ovarian cancer in the UK (including for women at high risk of the disease) because no test has been identified to reliably pick up ovarian cancer at an early stage. The UK Collaborative Trial of Ovarian Cancer Screening aimed to establish the effect of early detection of the disease by screening on ovarian cancer mortality. The preliminary study recruited over 200 000 women aged between 50 and 74 years and randomised them to either a control arm or one of two screening strategies: primary screening using measurement of serum CA-125 levels followed by TVUS as a second-line test; or TVUS alone. The two screening procedures were found to be similar in terms of sensitivity for all primary ovarian and fallopian tube cancers, but specificity was higher with combined screening.

Some genetic mutations are known to predispose women to ovarian cancer, e.g. *BRCA1* and *BRCA2* and the mismatch repair genes associated with Lynch syndrome families. *BRCA1* mutations confer a 39% lifetime risk of ovarian cancer up to the age of 70 years; this is 11–17% for *BRCA2* mutations up to the age of 70 years. The mismatch repair genes confer an increased lifetime risk of ovarian cancer of 9–12% in addition to the increased risk of endometrial cancer. Referral to a specialist cancer genetics service is advisable. Women at high risk of ovarian cancer may be offered risk-reducing surgery in the form of prophylactic bilateral salpingo-oophorectomy,

Joe Vincent Meigs, 1892–1964, gynaecological surgeon, Massachusetts General Hospital, Boston, MA, USA.

especially as they may also be at increased risk of breast cancer with some evidence suggesting that an oophorectomy can reduce the risk of breast cancer in these women.

Surgical staging of ovarian cancer (*Table 87.15*) is performed at laparotomy via a midline incision if disease is suspected preoperatively by:

- careful evaluation of all peritoneal surfaces;
- four washings of the peritoneal cavity: diaphragm, right and left abdomen, pelvis;
- infracolic omentectomy;
- selected lymphadenectomy of the pelvic and para-aortic lymph nodes;
- biopsy and/or resection of suspicious lesions, masses and adhesions;
- random blind biopsies of normal peritoneal surfaces, including that from the undersurface of the right hemidiaphragm, bladder reflection, cul-de-sac, right and left paracolic recesses and both pelvic side walls;
- total abdominal hysterectomy and bilateral salpingo-oophorectomy;
- appendicectomy for mucinous tumours; if a routine appendicectomy results in an intraoperative suspicion of a mucinous tumour, the surgeon should take washings and a biopsy from suspicious area(s).

TABLE 87.15 Condensed staging of ovarian cancer.

Stage I	Growth limited to the ovaries
Stage II	Growth involving one or both ovaries with pelvic extension (uterus, bladder, sigmoid colon, rectum) or primary peritoneal cancer but not including the lymph nodes
Stage III	Tumour involving one or both ovaries with histologically confirmed peritoneal implants outside of the pelvis including spread to retroperitoneal lymph nodes (pelvic and/or para-aortic) only
Stage IV	Growth involving one or both ovaries with distant metastases

The general principle is cytoreductive surgery followed by combination chemotherapy; only a minority of patients with ovarian cancer require a bowel resection during the primary procedure or surgery for recurrent disease. The only exception to this rule is a young woman with stage I disease or a borderline tumour who requests a unilateral oophorectomy to conserve her fertility.

Fertility preservation in the form of controlled ovarian stimulation with oocyte or embryo cryopreservation has been undertaken in patients with low-grade tumours (grade IA/B) who wish to preserve their fertility; however, the effect of this on the underlying disease process is not known, with the additional risk of seeding the cancer during oocyte retrieval. This must, therefore, be carried out with caution and under the guidance of oncological specialists. Ovarian tissue cryopreservation at the time of cytoreductive surgery has also been undertaken, holding the promise for *in vitro* maturation of oocytes in the future. Autologous transplantation would be contraindicated as it has the risk of cancer recurrence.

FURTHER READING

British Association for Sexual Health and HIV. *UK national guideline for the management of pelvic inflammatory disease*. Macclesfield, UK: BASHH, 2011. Available from https://www.bashh.org/documents/3572.pdf.

European Society of Human Reproduction and Embryology (ESHRE). Guideline on the management of women with endometriosis. Available from https://www.eshre.eu/Guidelines-and-Legal/Guidelines/Endometriosis-guideline.aspx.

National Institute for Health and Care Excellence. *Guidance on ectopic pregnancy and miscarriage: diagnosis and initial management*. NICE Guideline 126. London: NICE, last updated, 2021. Available from https://www.nice.org.uk/guidance/ng126.

National Institute for Health and Care Excellence. *Guidance on heavy menstrual bleeding: assessment and management*. NICE Guideline 88. London: NICE, last updated, 2021. Available from https://www.nice.org.uk/guidance/ng88.

NHS Cervical Screening Programme. Available from https://www.gov.uk/guidance/cervical-screening-programme-overview.

Prat J, FIGO Committee on Gynaecologic Oncology. Staging classification for cancer of the ovary, fallopian tube, and peritoneum. *Int J Gynaecol Obstet* 2014; **124**(1): 1–5.

Royal College of Obstetricians and Gynaecologists. *Green-top guidelines on ovarian cysts in postmenopausal women*. Green-top Guideline no. 34. London: RCOG, 2017. Available from http://www.rcog.org.uk/en/guidelines-research-services/guidelines/gtg34/.

Royal College of Obstetricians and Gynaecologists. *Green-top guidelines on management of suspected ovarian masses in premenopausal women*. Green-top Guideline no. 62. London: RCOG, 2014. Available from http://www.rcog.org.uk/en/guidelines-research-services/guidelines/gtg62/.

Scottish Intercollegiate Guidelines Network. *Management of epithelial ovarian cancer*. SIGN 135. Edinburgh: SIGN, 2018. Available from https://www.sign.ac.uk/media/1073/sign135_oct2018.pdf.